

B. Świczko-Żurek¹, A. Szumlański², J. Zorn¹

¹Faculty Of Mechanical Engineering, Technical University of Gdansk, Narutowicza 11/12 Str., 80-952 Gdansk, Poland

²Hospital In Inowroclaw

ALLERGY TO IMPLANT COMPONENTS: CHROMIUM, NICKEL, COBALT AND TITANIUM

ABSTRACT

An implant is composed of different metals, such as: nickel, chromium, cobalt, titanium, molybdenum and vanadium. Some metals may cause eczema like rash or scattered vesiculopapular dermatitis and urticaria. Allergies may result in loosening the implants, bone joints and orthopedic prosthesis. The preliminary research results carried out on the patients with eczema to the components of implants. The research was performed in Hospital in Inowroclaw and it is included in master thesis of a graduate from Technical University of Gdansk.

Key words: implants, allergy

INTRODUCTION

Stainless steel, cobalt and titanium alloys belong to the metals, the most often used in orthopedics. The chemical composition of these alloys is presented in Tabl.1. Recently the stainless steel without Ni has been proposed for patients allergic to Ni [1-4].

Table.1. Composition of metals of separate elements, most frequently used in orthopedic, pct [3]

| The alloy | Nickel | Cobalt | Chromium | Titanium | Molybdenum | Aluminum | Vanadium |
|------------------------|---------------|---------------|-----------------|-----------------|-------------------|-----------------|-----------------|
| Stainless steel | 13-15 | - | 17-19 | - | 2-4 | - | - |
| Cobalt alloy | - | 62-67 | 27-30 | - | 5-7 | - | - |
| Titanium alloy | - | - | - | 81-91 | - | 5,5-6,5 | - |

The chemical composition of implants must be well known while examining allergies to different components. The cobalt-chromium and titanium alloys may contain small amounts of Ni. An allergy to titanium may be mistakenly recognized without considering the amount of Ni in titanium alloy [5,6].

Contemporary achievements in metallurgy result in improved quality of metallic orthopaedic implants which are: biologically indifferent, resistable to abrasion, have little inclination to corrosion and proper endurance [7].

The physicochemical condition of the surface of metallic implants is subjected to changes as a result of electrical conduction, corrosion and friction processes. The implant surface is influenced by the surrounding tissue and body liquids. Moreover the microorganisms, which sticking to the implant may cause diseases. The presence of bacterias and biofilms on the implant surfaces changes the reactions of immunological system [1,8].

Many scientific works concerning corrosion and wearing out of metal implants have appeared. It has been found, that contact with blood, sweat and saliva causes releasing metals from stainless steels [1-3]. Presence of Ni in tissues surrounding the implant has been confirmed. In addition some traces of abrasive wear have been found in the implant area [8].

The research concerning the release of metals from the properly functioning of hip endoprothesis showed some amounts of chromium and cobalt from cobalt-chromium alloy and the release of Ti from Ti endoprothesis. These elements were discovered in the blood and urine and their intensity depending on the duration of implants' stay in the body [9].

In the research conducted on the rabbits allergic to Ni in which the intramedullary nails for tibial fracture fixation were applied, showed decrease in the endurance of bones, increase in the absorption, decreased amount of osteocytes and worse rebuilding of bone tissue [10].

In some cases clinical allergic evidences resulted in the removal of the implant due to heavy skin inflammation, urticaria and vasculitis. Skin changes may appear as rash located close to the implant or scattered all over the body eczema haematogenes. After applying metal joints in tibial fractured treatment as well as the metalosis, which means metallic coloring of the surrounding tissues. It results in muscles necrosis [1,11-13].

Szumlanski found that aseptic fistula became the gate of infection appeared in the body of the patients, whose implants worked improperly. The patients who suffered the complication were allergic to the metals included in the implant [2,14].

The main aim of the work was to estimate allergic reaction to patch tests. The erythema, clods, follicles and edema were considered.

MATERIALS AND METHODS

The patch tests (Fig.1) were used for the research, which was carried on 6 selected patients, before and after surgical intervention.

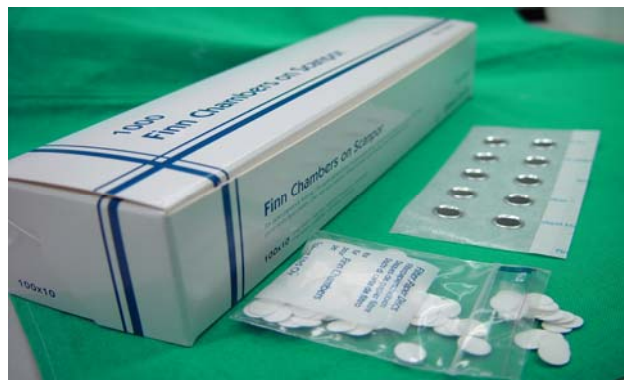

Fig.1. The patch tests were used for the research

The way of making the tests is shown in the Fig.2

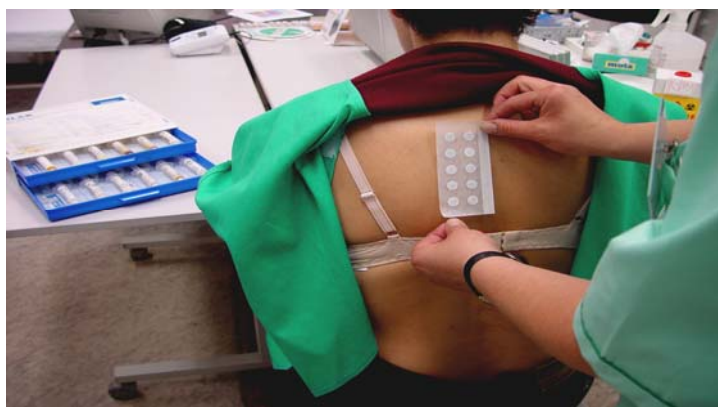


Fig.2. The way of attaching patch tests with the chosen allergic compounds to the body (Ni,Cr,Co,V,Ti)

RESEARCH RESULTS AND DISCUSSION

Up-to-date reports there are completely different opinions concerning the patch tests performed before and after the operation. Some doctors claim that the patch tests should be carried on before the surgical treatment [11,13,14], while the others think there is no need carrying them on at all. There is also an opinion that the patch tests should be performed, if there are some complications [10]. It should be mentioned that complications which result from allergy to metals may occur without any skin irritation and show negative patch tests [15]. In that case so called revision operations are performed. They require much experience from the operating staff in doing bone grafts or using implant with special structures [2].

The patients (6) were subjected to the tests on the Ni, Cr, Co allergens (Fig.3).

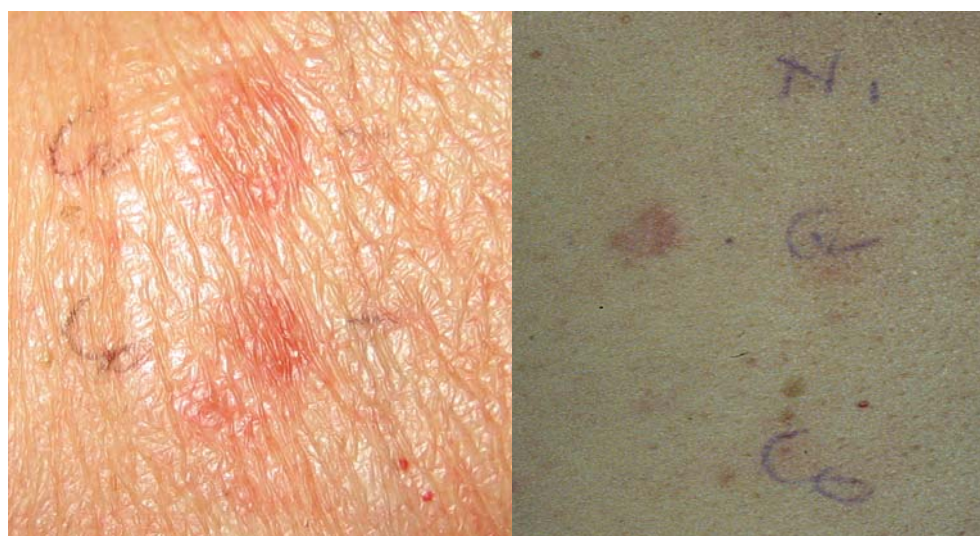

Fig.3. Skin changes after performing the tests

Two of them (1,2) had their implants removed due to aseptic loosening and intolerance of endoprosthesis. It resulted in pain, fistula serosa and edema. There were found to have oversensitiveness to Cr and Co. The allergic were not diminished by using antihistaminic drugs (Fig.4).

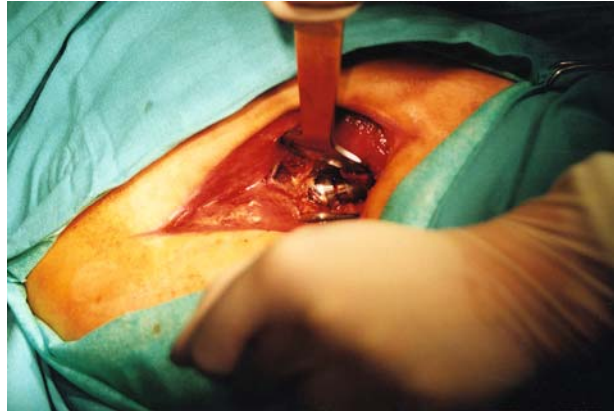

Fig.4. The hip implant removing caused by aseptic loosening

The patient (3) with Ni allergy suffered from skin imperfections after introducing hip implant (Fig.5). The symptoms decreased after applying antihistaminic drugs.

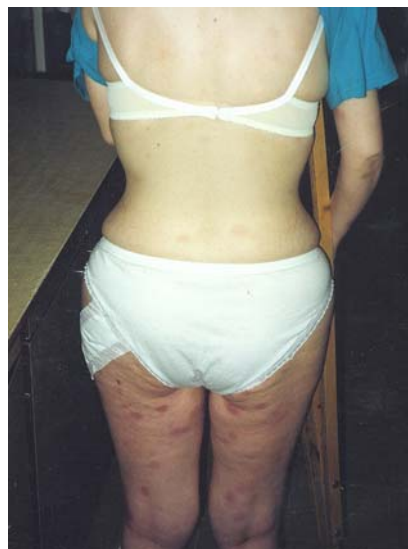

Fig.5. The patient with Ni sensitiveness after applying hip prothesis

Another is the case with the patient (4) allergic to Ni and Co, who had no symptom of oversensitiveness up to 2 weeks. Then fistula serosa aseptica occurred in the hip (Fig.6). Patch tests were repeated. They showed allergy to Ti. The histaminic drugs decreased the symptoms.

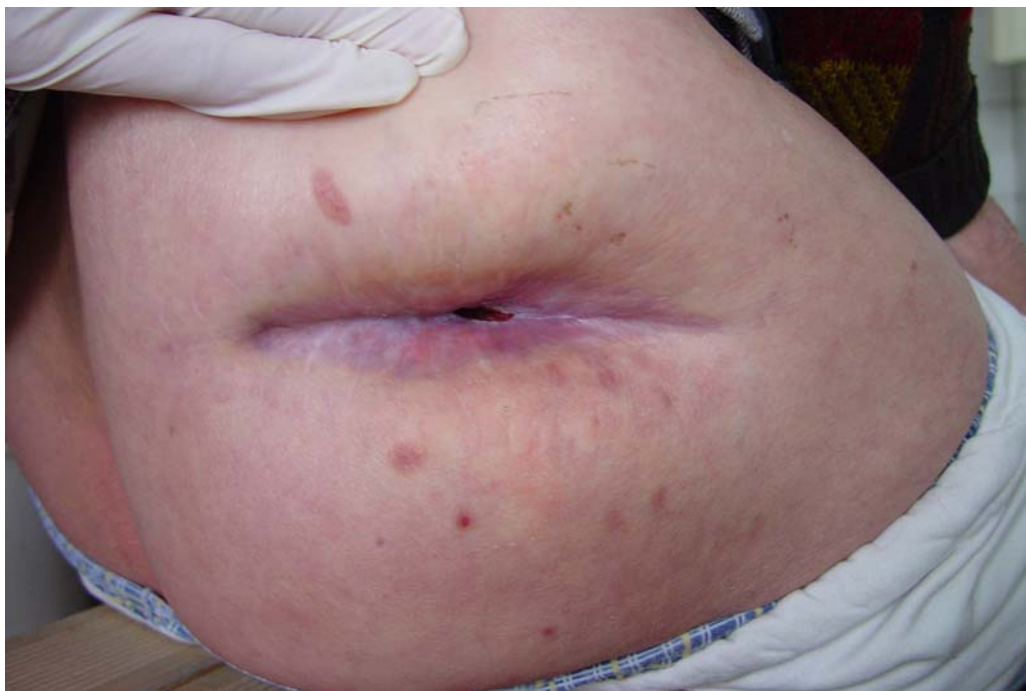

Fig.6. The fistula serosa in hip after implantation

The patients (5,6) whose bones were joint with ZESPOL method, positive reaction to Cr and Ni was found. It appeared as contact dermatitis covering a large area of the skin, not only in the implant-tissue area (Fig.7). Some disturbances in the bone growth was observed. Treatment with antyallegic drugs was ineffective. After 4 weeks the implants were removed and the patients were treated in cast.

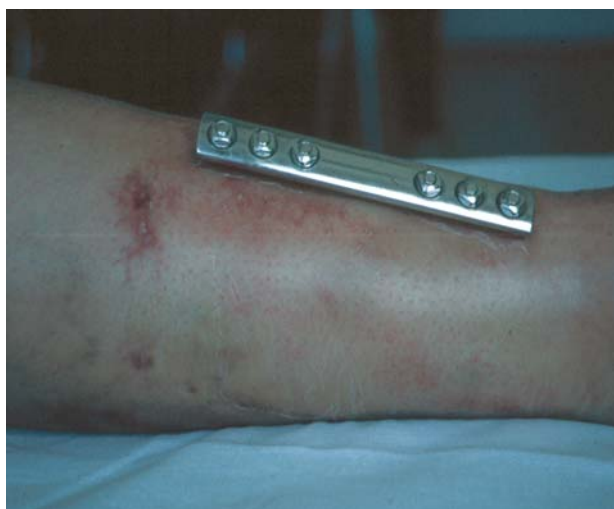

Fig.7. The contact dermatitis on the skin surface

CONCLUSIONS

In surgery with the use of metallic implant introduced „by force”, while it is impossible to conduct the patch tests premeditation is necessary. If it appears alternative or another treatment should be applied.

Implants introduced into human bodies contain big amount of compounds causing irritation and allergic reactions. When the pharmacological methods are not effective, the removal of the implant is the only solution.

Long contact of these elements with the alive tissue causes penetration of metal ions into the human body. Consequently it may result in serious allergic disturbances – as it was in the case mentioned above, but also to penetration of some body organs by the metal elements and cause unreversible changes.

REFERENCES

1. Swierczyńska-Machura D., Kiec-Swierczyńska M., Krecisz B., Pałczyński C.: Allergy to implant compounds. *Allergy, Asthma, Immunology* 2004; 9; 128-132.
2. Szumlanski A.: Allergy to chromium, nickel and cobalt with trauma-orthopedic patients. PhD, Military Academy in Lodz, Lodz 2002.
3. Hallab N.J., Merritt K., Jacobs J.J.: Metal sensitivity in patients with orthopaedic implants. *J. Bone Joint Surg. Am.* 2001; 83-A; 428-436.
4. Disegi J.A., Eschbach L.: Stainless steel in bone surgery. *Int. J. Care Injured* 2000; 31; (suppl.4); 2-6.
5. Holzwarth U., Thomas P., Kachler W. et al.: Metallurgical differentiation of cobalt-chromium alloys for implants. *Orthopade* 2005; 34; 1046-7; 1049-51.
6. Schuh A., Thomas P., Kachler W. et al.: Allergic potential of titanium implants. *Orthopade* 2005; 34; 327-8; 330-3.
7. Balin A., Toborek J.: The impact of material and structure features of hip implants on its biofunctioning. *Orthopaedic Quarterly* 1998; 2; 124-33.
8. Hierholzer S., Hierholzer G., Sauer K.H., Paterson R.S.: Increased corrosion of stainless steel implants in infected plates fractures. *Arch. Orthop. Trauma Surg* 1984; 102; 198-200.
9. Jacobs J.J., Skipor A.K., Patterson L.M. et al.: Metal release in patients who have had a primary total hip arthroplasty. A prospective, controlled, longitudinal study. *J. Bone Joint Surg. Am.* 1998; 80; 1447-58.
10. Oiso N., Komeda T., Fukai K. et al.: Metal allergy to implanted orthopaedic prosthesis after postoperative *Staphylococcus aureus* infection. *Contact Dermatitis* 2004; 51; 151-3.

11. Spiewak R., Brewczynski P.Z.: Complications after stabilizing with metallic implant fracture of femour with a person suffering contact allergy with Cr, Ni and Co. *The Polish Medical Weekly* 1993; 48; 651-2.
12. Szumlanski A., Buczyłko K., Weiss W.: Oversensitiveness to Ni, Cr and Co as a cause of complications with trauma-orthopaedic patients. *Orthopaedic and traumatology on the verte of the New Millenium. The Meeting of Polish Orthopaedic and Traumatology Society, Bydgoszcz* 2002; 256-9.
13. Tuszynski W., Kurowska-Madejska Z.: The importance of allergic skin tests on the Co-Cr-Mo alloy and the steel after applying implants and bone joining materials. *Motion Surgery of Polish Orthopaedics* 1986;6; 482-5.
14. Buczyłko K., Szumlanski A.: Introducing the implant with some amount of Ni into the body of a person allergic to that metal may cause complications. *The Medicine Poulse* 2003; 6;55.
15. Schoberl A., Summer B., Jakob A.T. et al.: Periimplantar cobalt-specific DTH reaction in patch test negative patient with failure of hip arthroplasty. *J. Allergy Clin. Immunol.* 2004; 2 suppl.; 250-1.