

# Journal of Biomedical Optics

BiomedicalOptics.SPIEDigitalLibrary.org

## Application of the laser diode with central wavelength 975 nm for the therapy of neurofibroma and hemangiomas

Jacek Szymańczyk  
Mirosław Sawczak  
Witold Cenian  
Katarzyna Karpienko  
Małgorzata Jędrzejewska-Szczerska  
Adam Cenian

**SPIE.**

Jacek Szymańczyk, [Mirosław Sawczak](#), Witold Cenian, Katarzyna Karpienko, Małgorzata Jędrzejewska-Szczerska, Adam Cenian, "Application of the laser diode with central wavelength 975 nm for the therapy of neurofibroma and hemangiomas," *J. Biomed. Opt.* **22**(1), 010502 (2017), doi: 10.1117/1.JBO.22.1.010502.

# Application of the laser diode with central wavelength 975 nm for the therapy of neurofibroma and hemangiomas

Jacek Szymańczyk,<sup>a</sup> Mirosław Sawczak,<sup>b</sup>  
Witold Cenian,<sup>b</sup> Katarzyna Karpienko,<sup>c</sup>  
Małgorzata Jędrzejewska-Szczerska,<sup>c,\*</sup> and  
Adam Cenian<sup>b,\*</sup>

<sup>a</sup>Medical University of Warsaw, Department of Dermatology,  
82a Koszykowa Street, Warsaw 02-008, Poland

<sup>b</sup>Polish Academy of Sciences, Szewalski Institute of Fluid-flow  
Machinery, Department of Physical Aspects of Ecoenergy,  
14 Fiszerka Street, Gdansk 80-952, Poland

<sup>c</sup>Gdansk University of Technology, Faculty of Electronics,  
Telecommunications and Informatics, Department of Metrology and  
Optoelectronics, 11/12 Narutowicza Street, Gdansk 80-233, Poland

**Abstract.** This paper presents a newly developed dermatological laser (with a central wavelength 975 nm) for application in therapies requiring deep penetration of tissue, e.g., cutaneous (dermal) neurofibroma (von Recklinghausen disease) and hemangiomas. This laser can work either in pulses or continuous wave mode. Laser radiation is transmitted toward the application region by optical fiber with a diameter of 0.6 mm. The compact design of the laser facilitates its transport and increases the comfort of use.

© 2017 Society of Photo-Optical Instrumentation Engineers (SPIE) [DOI: 10.1117/1.JBO.22.1.010502]

Keywords: laser diode; lasers; dermatology.

Paper 160626LRR received Sep. 8, 2016; accepted for publication Jan. 6, 2017; published online Jan. 26, 2017.

## 1 Introduction

The high number of dermatological disorders (such as von Recklinghausen disease, hemangiomas, etc.) is affecting the life expectancy and its quality of the aging population.

Von Recklinghausen disease (neurofibroma) is an autosomal dominant disorder characterized by multiple neurofibromas, café au lait spots, and Lisch nodules of the iris, which can change during a lifetime. In this disease, other disorders, from physical disfigurement and pain to cognitive disability, may occur.<sup>1</sup> The prevalence of this tumor is 1 in 3000 live births in Western countries, making it a relatively common skin disorder. The disease is treated using drug and nondrug therapies. Usually, as a nondrug therapy, laser therapy is used, especially using a CO<sub>2</sub> laser (10.6 μm) with continuous wave<sup>2</sup> but also a Ho:YAG laser. According to previous studies,<sup>3</sup> treatment with a

continuous wave CO<sub>2</sub> laser can result in hypertrophic and atrophic scars. As hypertrophic scars can develop 2 months after therapy, the authors of Ref. 2 have recommended a preliminary test be performed to enable the patient to see the results to be expected. A deeper penetration of radiation into distorted tissue can be achieved when the Ho:YAG laser (with a central wavelength 2100 nm)<sup>4</sup> is used. However, in the case of therapy with a Ho:YAG laser, a singular irradiation rarely results in positive therapeutic and cosmetic outcomes, i.e., it leaves a flat scar on the skin surface. Consequently, usually after the initial healing period, irradiation must be repeated.

A hemangioma is a soft tissue tumor composed of variably mature blood vessels and endothelial cells.<sup>5</sup> This tumor occurs primarily among young children. Typically, it is treated pharmacologically with good effects.<sup>6,7</sup> However, surgical intervention is necessary when the pharmacological treatment was not successful.<sup>6</sup> Pathological changes can be so large that they may cover more than half of the patient's face. Serious problems with a child's health can occur when lesions on the nose prevent proper breathing or on the eye, affecting seeing. In the past few years, new optoelectronic products for dermatological therapy have been developed. A pulsed dye laser with wavelengths 595 nm and long pulses has been successfully used for the treatment of very early, flat, superficial hemangiomas if they appear in cosmetically significant areas.<sup>8</sup> Unfortunately, raised lesions or lesions under the skin do not respond to this laser treatment. On the other hand, the treatment with a Nd:YAG laser<sup>9</sup> often led to some sort of scar due to deep distortion of the skin. The healing process is usually slow, and the therapy should be repeated several times to achieve an adequate cosmetic effect.

The diode lasers with a central wavelength 975 nm have not been widely used up until now in clinical therapies. A few examples related to otolaryngology procedures are known: turbinate reduction, nasal polypectomy, ablation of an oral papilloma, photocoagulation of nasal telangiectasias, and laser-assisted liposuction.<sup>10-12</sup> These studies determined optimal laser settings for therapy of cutaneous lesions. In our investigations, we used a laser diode with a wavelength 975 nm because the radiation penetrates deeper into the biological tissue in comparison to the Ho:YAG laser but not so deep as the Nd:YAG laser. This is particularly important in the case of pathological changes of the skin resulting from neurofibroma (von Recklinghausen disease). The author's (MD J. Szymańczyk) clinical practice related to neurofibroma therapy (with Nd:YAG and Ho:YAG lasers) showed that it is necessary to use a laser that allows deeper penetration of the skin than Ho:YAG.

In this article, a newly developed laser with a central wavelength of 975 nm for dermatological treatment<sup>13</sup> is presented; the laser ensures different tissue penetration than both Ho:YAG and Nd:YAG. The comparison of effects for therapies with pulsed and continuous radiation at various output powers was performed. It was applied for therapies requiring deep penetration of tissue, e.g., cutaneous (dermal) neurofibroma or hemangiomas. The preliminary investigation showed the usefulness of such a laser during von Recklinghausen disease or hemangioma treatment.

## 2 Materials and Methods

The 20-W dermatologic diode laser radiating at 975 nm with the parameters as follows: continuous wave or pulsed mode, duration of pulse ( $\tau = 0.05 \text{ ms} \div 300 \text{ ms}$  with step  $\Delta\tau = 100 \text{ ns}$ ),

\*Address all correspondence to: Małgorzata Jędrzejewska-Szczerska, E-mail: mjedrzej@eti.pg.gda.pl; Adam Cenian, E-mail: cenian@imp.gda.pl

and pulse period ( $T = 50 \text{ ms} \div 500 \text{ ms}$  with step  $\Delta T = 10 \text{ ms}$ ), have been used in the experiment (see Fig. 1). Both pulse duration and pulse period could not be changed continuously but stepwise, with the steps described above.

The compact size of the laser enables its easy transportation to the locations where laser radiation is going to be applied. The laser was equipped with a dedicated optical head protecting the optical fiber end and allowing laser radiation transmission to the treated regions (Fig. 2). The flat, polished end of the quartz fiber is placed in a metal needle. The end can be polished again in the case of any damage. The core diameter of the optical fiber, applied to transmit diode radiation up to the SMA connector placed at laser chassis, is  $110 \mu\text{m}$ . To this SMA connector the optical head is connected using fiber with a wider core diameter of  $600 \mu\text{m}$  [see Fig. 2(a)].

Preliminary studies were performed using developed optical tissue-mimicking phantoms, materials that simulate the optical properties of human skin.<sup>14-17</sup> These studies were carried out to test the laser interaction with the skin. The temperature distribution in the phantom after laser radiation was examined to determine the optimal and safe laser parameters (power, pulse duration, and its repetition rate) during treatment. The interaction of the 975-nm laser radiation with tissue phantoms<sup>18</sup> was studied as a preclinical trial of laser treatment effects.

### 3 Results

The dermatologic diode laser was applied for treatment of cutaneous human tissue due to dermal neurofibroma and hemangiomas. The selected patients had been already treated using standard Nd:YAG (with a central wavelength 1064 nm) laser

therapy. This enabled the comparison of results and effectiveness of this new therapy using the diode laser (with a central wavelength 975 nm). To diminish the discomfort related to the laser therapy, it was preceded by local anesthesia with 1% of lignocaine.

#### 3.1 Laser Therapy of Dermal Neurofibroma

In the case of the patient with dermal neurofibroma, different laser power levels were applied to determine the optimum power. In the first case, laser radiation with a continuous wave 10 and 12 W was applied (Fig. 3).

The cutaneous (dermal) neurofibroma manifests as single or multiple firm, rubbery bumps of varying sizes on a person's skin. They are not malignant but progressive in number and size. They can result in a range of symptoms from physical disfigurement and pain to cognitive disability.

The neurofibroma symptoms mentioned above, i.e., rubbery bumps of various sizes at the right side of the patient neck region, were treated using continuous wave optical radiation 975 nm of the diode laser. Due to the tolerability of the therapy using both diode (975 nm) and Nd:YAG (1064 nm) lasers, the treatment was preceded by local anesthesia with 1% of lignocaine.

The interaction time of laser radiation with the bumps varied with their size and applied laser power. This must be properly determined to achieve good therapeutic and cosmetic results. The interaction time increases with the size of the bump and decrease of laser power. The inside of the bumps is filled with slimy tissue that must be evaporated. If the interaction time is too short then part of the bump survives. When it is too long, unnecessary deep scars result. In the case discussed, laser radiation was applied for at least 3 s for bumps of 1.8 mm in diameter and more than 5 s for bumps 3 mm in diameter.

The final effects of the diode-laser therapy on cutaneous (dermal) neurofibroma are very promising. It was found that the radiation power of 10 W is optimal for the neurofibroma therapy, i.e., 10 W was enough to get positive effects and have a good speed of laser therapy. The positive effects mean no bleeding during therapy and no scars after healing process, i.e., increased life comfort and good cosmetic effects even after one laser treatment. However, after some years the repetition of the treatment may be required if the cause for the pathological




Fig. 1 Experimental setup: (a) dermatological laser and (b) control panel of the laser.

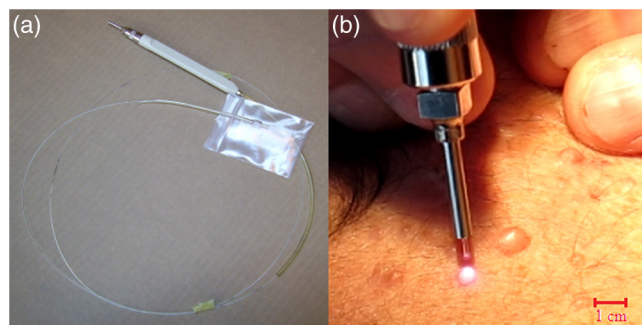
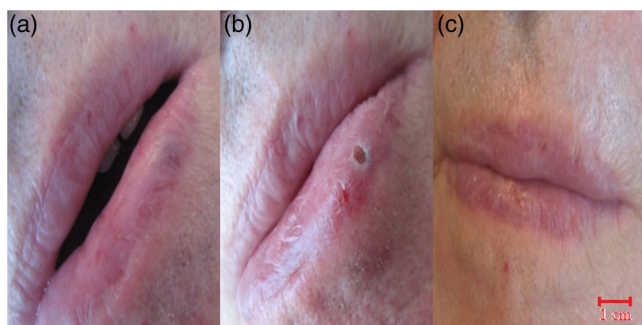


Fig. 2 (a) Optical head protecting fiber and (b) allowing laser-radiation transmission to treated region.

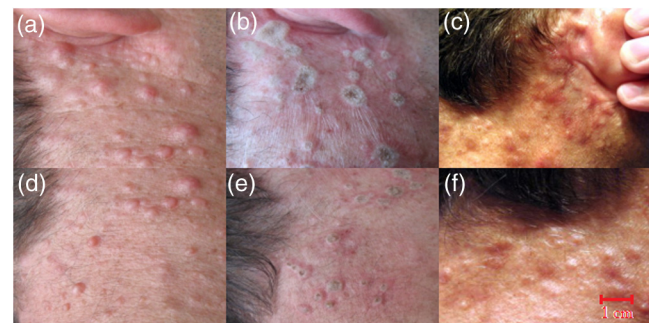

Fig. 3 Laser therapy of cutaneous (dermal) neurofibroma using radiation with wavelengths 975 nm and continuous wave, power: 12 W right side of the neck region below ear (a) view before irradiation, (b) soon after irradiation (55 s), (c) 7 weeks after laser treatment and 10 W right side of the neck region below the first treatment, (d) view before irradiation, (e) soon after irradiation (52 s), and (f) 7 weeks after laser treatment. Example of a figure caption: (a) sun and (b) blob.



**Fig. 4** Laser therapy of a hemangioma located at lower lip; radiation wavelength 975 nm and continuous wave power 10 W, view: (a) before irradiation, (b) soon after irradiation (7.5 s), and (c) 7 weeks after laser treatment.

skin change is not removed completely. The speed of therapy is determined by the time needed to remove rubbery bumps of various sizes.

In the case of therapy with Ho:YAG laser, it was established<sup>7</sup> that singular irradiation never achieves positive therapeutic and cosmetic effects, i.e., it leaves a flat scar on the skin surface. So usually, after the healing period, irradiation must be repeated, as the previously treated neurofibroma again raises above skin level in the central part. In the case of the applied diode laser, this negative effect was not observed. Singular irradiation led to flat scars on the skin surface, so the improved cosmetic effect of the diode-laser therapy was gladly welcomed by patients. It was also established that the treatment with the diode laser (975 nm) is faster than with the Nd:YAG laser (1064 nm).

### 3.2 Laser Therapy of Hemangiomas

The second patient with a hemangioma located at the lower lip was irradiated using the same diode laser with continuous wave optical radiation at 10 W power (see Fig. 4). The laser radiation was applied for 7.5 s. There was no sign of scarring observed 4 days after treatment [see Fig. 4(c)].

## 4 Discussion

The preliminary investigations of laser diode therapies (generating radiation with a wavelength 975 nm) directed toward treatment of cutaneous human tissue, both dermal neurofibroma (von Recklinghausen disease) and hemangiomas, show very positive and promising results (see Table 1).

The positive effects mean no bleeding during therapy and no scars after the healing process, i.e., increased life comfort and good cosmetic effects even after one laser treatment. However, after some years, the repetition of the treatment may be required as the reason for the pathological skin changes is not removed.

The results for treatment of neurofibroma with diode laser radiation (975 nm) are better than in the case of Ho:YAG laser (2100 nm) therapy; however, these results should be verified by checking against a larger sample of patients.

In case of the hemangioma treatments, not every case was successful in terms of cosmetic effects. However, in the case of using the new laser in the curing process of patients with neurofibroma, very good therapeutic and cosmetic effects were achieved. Moreover, we could observe those positive effects not only after 1 month but also after 1 year.

**Table 1** Results of treatment of cutaneous human tissue, both dermal neurofibroma (von Recklinghausen disease) and hemangiomas.

ID	Diagnosis	Laser parameters		Good therapeutic and cosmetic effect <sup>a</sup>
		Power (W)	Operation mode	
1	Hemangioma	10	cw	+/-
2	Neurofibroma	10	cw	+/+
3	Neurofibroma	15	Pulsed, 50 ms 10 Hz	+/+
4	Neurofibroma	10	cw	+/+
5	Neurofibroma	10	cw	+/+
6	Neurofibroma	12	cw	+/+
7	Neurofibroma	5	cw	+/+
8	Neurofibroma	12	cw	+/+
9	Hemangioma	5	cw	+/-
10	Hemangioma	5	cw	+/+
11	Hemangioma	10	cw	+/-

Note: +/+, Good therapeutic and cosmetic effect.  
 +/-, Good therapeutic and not completely satisfactory cosmetic effects.  
 +/- - Good therapeutic and medium cosmetic effect (some sort of scar present).  
<sup>a</sup>Observation based on clinical experience of the medical doctor J. Szymańczyk and photographic documentation.

### Disclosures

No conflicts of interest, financial or otherwise, are declared by the authors.

### Acknowledgments

The authors acknowledge the financial support from the National Science Centre (NCN—Poland), projects No. 2914/B/T02/2011/40 and No. 2011/03/D/ST7/03540. Małgorzata Jędrzejewska-Szczerska and Katarzyna Karpieńko also acknowledge the support of COST Action BM1205, as well as DS Programs of the Faculty of Electronics, Telecommunications and Informatics, Gdańsk University of Technology. The study was approved by the Bioethics Committee at the Regional Medical Chamber in Warsaw, Poland (Resolution No 4/14).

### References

1. M. H. Shen et al., "Molecular genetics of neurofibromatosis type 1 (NF1)," *J. Med. Genet.* **33**, 2–17 (1996).
2. Y. Z. Chiang et al., "Carbon dioxide laser treatment of cutaneous neurofibromas," *Dermatol. Ther.* **2**(1), 7 (2012).
3. J. U. Ostertag et al., "Hypertrophic scars after therapy with CO<sub>2</sub> laser for treatment of multiple cutaneous neurofibromas," *Clin. Orthop. Relat. Res.* **28**(3), 296–298 (2002).
4. D. Goldberg, *Laser Dermatology*, 2nd ed., Springer-Verlag, Berlin, Heidelberg (2013).
5. L. Thompson, *Head and Neck Pathology*, 2nd ed., Elsevier Saunders, Philadelphia (2013).

6. A. V. Moyakine et al., "Propranolol treatment of infantile hemangioma (IH) is not associated with developmental risk or growth impairment at age 4 years," *J. Am. Acad. Dermatol.* **75**(1), 59–63 (2016).
7. J. Miquel et al., "Successful treatment of multifocal intracerebral and spinal hemangiomas with propranolol," *J. Am. Acad. Dermatol.* **70**(4), e83–e84 (2014).
8. C. Rizzo et al., "Outcomes of childhood hemangiomas treated with the pulsed dye laser with dynamic cooling: a retrospective chart analysis," *Dermatol. Surg.* **35**(12), 1947–1954 (2009).
9. R. W. Waynant, *Lasers in Medicine*, CRC Press, Boca Raton, Florida (2001).
10. J. Newman et al., "Applications of the diode laser in otolaryngology," *Ear Nose Throat J.* **81**(12), 850–851 (2002).
11. J. P. Reynaud et al., "Lipolysis using a 980-nm diode laser: a retrospective analysis of 534 procedures," *Aesthetic Plast. Surg.* **33**(1), 28–36 (2009).
12. R. A. Weiss et al., "Laser-assisted liposuction using a novel blend of lipid- and water-selective wavelengths," *Lasers Surg. Med.* **41**(10), 760–766 (2009).
13. L. Piechowski, W. Cenian, and A. Cenian, "Pulsed dermatologic 20 W diode-laser emitting at 975 nm," *Proc. SPIE* **8703**, 870304 (2012).
14. M. S. Wróbel et al., "Nanoparticle-free tissue-mimicking phantoms with intrinsic scattering," *Biomed. Opt. Express* **7**(6), 2088–2094 (2016).
15. M. S. Wróbel et al., "Multi-layered tissue head phantoms for non-invasive optical diagnostics," *J. Innov. Opt. Health Sci.* **8**, 1541005 (2015).
16. M. S. Wróbel et al., "Measurements of fundamental properties of homogeneous tissue phantoms," *J. Biomed. Opt.* **20**(4), 045004 (2015).
17. M. Jędrzejewska-Szczerska et al., "Investigation of photothermolysis therapy of human skin diseases using optical phantoms," *Proc. SPIE* **9447**, 944715 (2015).
18. M. S. Wróbel et al., "Use of optical skin phantoms for pre-clinical evaluation of laser efficiency for skin lesion therapy," *J. Biomed. Opt.* **20**(8), 085003 (2015).