

## ORIGINAL PAPER

# Anterior subcutaneous transposition and simple decompression of the ulnar nerve at the elbow – the postoperative improvement in DASH score, VAS score and sonographic findings

Transpozycja podskórna przednia bądź prosta dekompresja nerwu łokciowego na poziomie rowka – ocena pooperacyjna przy pomocy kwestionariusza DASH, skali VAS oraz obrazowania ultrasonograficznego

Barbara Igielska-Bela<sup>1,2</sup>, Bogusław Baczkowski<sup>2</sup>, Karol Flisikowski<sup>3</sup>

<sup>1</sup> Orthopedic Department, Specialistic Hospital in Koscierzyna, Poland

<sup>2</sup> II Clinic of Orthopedy, Medical University of Gdansk, Poland

<sup>3</sup> Department of Management and Economics, Gdansk University of Technology, Poland

## Abstract

**Introduction.** Although a lot of studies have described long-term outcomes after surgical treatment of cubital tunnel syndrome, and the usefulness of sonography in diagnosing of this disorder, few studies have evaluated patients self-reporting outcomes or sonographic findings after surgery.

**Aim.** We assessed patients self-reporting instruments and sonographic findings in patients with the cubital tunnel syndrome before and after a surgery.

**Materials and methods.** Forty patients with moderate cubital tunnel syndrome admitted to an orthopedic department were included. Patients underwent an ultrasound examination, filled a DASH questionnaire before, three months and six months after the operation. They had also their symptoms rated with the VAS scale before and six months postoperatively. Patients with clinical signs of subluxation of the nerve during the operation were allocated to a "transposition" group. Patients without these signs had an in situ release. The statistical analyses were made using a nonparametric Friedman ANOVA test for DASH score and Wilcoxon matched-pairs signed-ranks test for VAS scale.

**Results.** After the in situ release, there was a higher difference in the cross-sectional area of the nerve three months after operations than in the cases with a subcutaneous transposition, respectively 10.9 mm<sup>2</sup> and 12 mm<sup>2</sup>. Patients satisfaction measured with the DASH questionnaire and the VAS scale showed that there was a statistically significant improvement after both operations.

**Conclusions.** According to our results, both methods help patients to relieve their symptoms, but after a simple decompression, recovery, measured with patients' self-reporting instruments and with ultrasound examination, is faster.

**Key words:** cubital tunnel syndrome, simple decompression, anterior subcutaneous transposition, ultrasound examination of the ulnar nerve.

## Streszczenie

**Wstęp.** Duża liczba badań naukowych opisuje odległe wyniki leczenia chirurgicznego zespołu rowka nerwu łokciowego, a także przydatność ultrasonografii w diagnozowaniu tego zaburzenia. Niewiele jest jednak badań, które oceniają subiektywne odczucia pacjentów po operacjach (kwestionariusz DASH) lub wyniki badań sonograficznych po operacji.

**Cel.** Celem naszego badania była ocena wyników kwestionariusza DASH oraz skali VAS i wyniki badań ultrasonograficznych u pacjentów z zespołem rowka nerwu łokciowego przed i po operacji.

**Materiał i metody.** Do badania włączono 40 pacjentów z umiarkowanym zespołem rowkiem nerwu łokciowego przyjętych do oddziału ortopedycznego. Pacjenci przeszli badanie ultrasonograficzne, wypełnili kwestionariusz DASH przed, trzy miesiące i sześć miesięcy po operacji. Swoje objawy oceniali także w skali VAS przed i sześć miesięcy po operacji. Pacjenci z objawami klinicznymi podwichnięcia nerwu podczas operacji zostali przydzieleni do grupy „transpozycji”. Pacjenci bez tych objawów mieli uwolnienie in situ. Do oceny wyników kwestionariusza DASH użyto testu nieparametrycznego Friedman ANOVA, dla skali VAS nieparametrycznego testu kolejności par Wilcoxon.

**Wyniki.** Po uwolnieniu in situ, przekrój nerwu w obrazie ultrasonograficznym był mniejszy trzy miesiące po operacji niż w przypadku transpozycji podskórnej, odpowiednio 10,9 mm<sup>2</sup> i 12 mm<sup>2</sup>. Zadowolenie pacjentów mierzone za pomocą kwestionariusza DASH i skali VAS wykazało, że nastąpiła statystycznie istotna poprawa po obu operacjach.

**Wnioski.** Zgodnie z naszymi wynikami, obie metody pomagają pacjentom złagodzić ich objawy, ale po prostej dekompresji powrót do zdrowia, mierzony przy pomocy kwestionariusza DASH, skali VAS oraz badaniem ultrasonograficznym, jest szybszy.

**Słowa kluczowe:** zespół rowka nerwu łokciowego, prosta dekompresja, transpozycja podskórna przednia, ultrasonografia nerwu łokciowego.

**Author's address:** Barbara Igielska-Bela, Specialistic Hospital in Koscierzyna, Orthopedic Department, ul. Piechowskiego 36, 83-400 Kościerzyna, Poland, phone: +48 58 686 05 53, e-mail 33030@gumed.edu.pl

Received: 08.05.2018

Accepted: 25.05.2018

Published: 30.06.2018



## Introduction

Neuropathy of the ulnar nerve at the elbow is the second most common neuropathy of the nerves in upper limb, after carpal tunnel syndrome [1, 2].

There are five well known anatomical structures which can cause the compression on the ulnar nerve: the arcade of Struthers, the medial intermuscular septum, the medial epicondyle, the arcuate ligament of Osborne, and the aponeurosis of flexor carpi ulnaris [1]. The nerve can be also compressed by tumors, ganglions, osteophytes or lipomas connected with the elbow joint. In some cases even disruption of medial head of triceps muscle can caused the neuropathy. The etiology of neuropathy is associated with post-traumatic elbow flexion, changes in morphology of the cubital tunnel due to joint arthrosis, or subluxation of the nerve. Elbow flexion has majority role in developing cubital tunnel syndrome. When elbow is in flex position, it comes down to cubital tunnel size reduction and to tensioning the arcuate ligament of Osborne [2, 3].

There are few classifications of the ulnar nerve neuropathy. According to Dellon's classification, the cubital tunnel syndrom is divided in three stages [4]. The first is mild when only periodic paresthesia or subjective feeling of hand weakness may occur. The moderate stage is when patient has paresthesia and weakness of his hand is measurable. The most severe stage is when complete disfunction of the nerve appear [3].

We can evaluate the ulnar nerve neuropathy at the elbow using standarized patient self-reporting instruments like DASH questionnaire, Michigan Hand Outcomes questionnaire or numbness and pain on the VAS scale. DASH questionnaire contains 30 questions about patients' symptoms during some daily activities. Michigan Hand questionnaire contains 6 scales: overall hand function, activities of daily living, pain, work performance, aesthetics and patients satisfaction.

When diagnosing the cubital tunnel syndrome we do not only look on signs and symptoms but also make an additional examination – nerve conduction studies. Although electrodiagnostic studies are usually sufficient to confirm the cubital tunnel syndrome, we have to remember that ulnar neuropathy at gyuon's tunnel or C8 radiculopathy or a lower brachial plexopathy can make this examination false positive.

Nowadays there are a lot of publications that show usefulness of ultrasonography in observing the morphology and dynamics of the ulnar nerve at the elbow [5]. During ultrasound examination a longitudinal and transverse views must be made. In most publications there are taken into account: the cross-sectional area of the ulnar nerve, presence of neural branches, presence of perineurium, presence of the hourglass' sign and subluxation of the nerve. Okamoto et al. made some dynamic sonographic studies and they showed

that ulnar nerve can move while flexing the elbow to the tip of the epicondyle or dislocated anteriorly [6]. It is described that sonographic signs of the cubital tunnel syndrome are hypoechoic nerve, higher cross sectional area of the nerve at the level of the epicondyle (the cut-off point is 10 mm<sup>2</sup>) and in some cases presence of hourglass' sign or subluxation of the nerve [5,6].

Treatment of the cubital tunnel syndrome can be operative and nonoperative. Nonoperative is reserved for mild syndrome or for people with contraindications to surgery and consist on physio- and pharmacotherapy.

Operative treatment of cubital tunnel syndrome has a hundred years old history [7]. There are a lot of surgical methods. We can divide them into two groups: in situ release and decompression with anterior transposition [1, 3, 8]. This anterior transposition can be subcutaneous, submuscular or intramuscular. We can also make simple decompression with epicondylectomy [9]. Nowadays there are a lot of reports about endoscopic decompression of the ulnar nerve [10].

## Aim

According to developing high resolution sonography of the limbs nerves we decided to investigate out patients before, three months and six months after surgery and compare the sonographic findings with patient self-reporting instruments.

## Materials and methods

We start the investigation after ethical approval provided by the Bioethical Committee of Medical University. Every participant was asked to sign written informed consent.

The examinations have been performed in accordance with the ethical standards as laid down in the 1964 Declaration of Helsinki and its later amendments or comparable ethical standards.

The investigation was performed between 2015 to 2017. Forty five patients admitted to Orthopedic Department with moderate cubital tunnel syndrome were included. 3 of them refused to participate in 3 months follow-up, 2 of them did not report for control after 6 months. We defined moderate stage of the disease using Dellon's classification. The cubital tunnel syndrome was also confirmed in electrophysiological examination. Previous traumas to the elbow with its deformity and recurrent cubital tunnel syndrome after previous surgery were exclusion criteria. Patients underwent ultrasound examination before operations. Typical views of nerve (longitudinal and transverse) were taken using linear 5-12 MHz probe, Sonoscape S8. We used the elevator technique. All US scans were performed by the same doctor. The investigators

were trained to perform ultrasound examination and had 5 year experience in musculoskeletal ultrasound. As the sonographic signs of cubital tunnel syndrome we took to consideration cross-sectional area of the nerve in transverse view, which in normal nerve should not exceed 9-10 mm<sup>2</sup> (Fig. 1) [5, 11], presence of neural branches (which in normal nerve should look as hyperechoic dots inside the hypoechoic nerve's matrix), presence of perineurium (which in normal nerve is

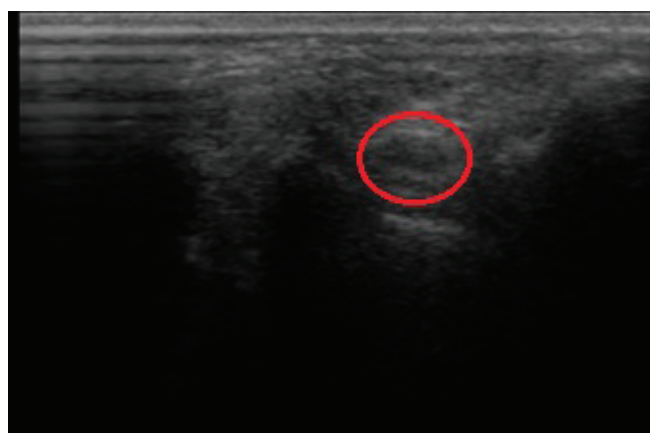


Fig. 1. . The ultrasonographic transverse view of the normal ulnar nerve at the elbow – in circle.

hyperechoic line), presence of hourglass' sign in longitudinal view (which is connected with pression on the nerve) and subluxation of the nerve while moving the limb. As subluxated nerve we defined the nerve which move to the tip of the epicondyle and/or dislocate anteriorly during elbow flexion. We did not make two groups of such patients. Participants were placed in sitting position and had their upper limb in a straight and a flex position at the elbow. After ultrasound examination patients were asked to fill DASH questionnaire and using visual analogue scale describe numbness and pain. Patients were qualified to operations. During operation when we found, after decompression of the nerve, luxation, we made anterior subcutaneous transposition. The operations were performed in accordance with the applicable standards. The surgeon had experience in both methods. Three months postoperatively patients had control ultrasound examination and once more filled DASH questionnaire, after six months they had ultrasound examination, filled DASH questionnaire, described numbness and pain using VAS scale. After

six months from operations we also asked patients about the overall hand function, activities of daily living, work performance and their satisfaction.

The data were collected using MS Excel 2013, and statistical analyses were made using Statistica 13.1. We performed Shapiro-Wilk normality tests for the whole set of analyzed variables (Tab. 1). We had to reject null hypothesis about normality of DASH distribution, so we had to compare those variables with the use of nonparametric tests: with Friedman ANOVA test for DASH before, three months and six months after the operation and Wilcoxon matched-pairs signed-ranks test for VAS before and six months after the operation.

## Results

We performed ultrasound examination in 40 patients (19 women and 21 men) with moderate cubital tunnel syndrome before, three and six months after operations. Patients average age was 54,5 years. In 20 cases cubital tunnel syndrome concerned right upper limb and in 20 cases left one. The signs of the cubital tunnel syndrome were numbness and tingling of the IV and V finger, elbow pain and positive Tinel's test, crossed finger test and Froment's sign. There were not cases with muscles atrophy. The average duration of symptoms prior to orthopedic consultation was 217 days and prior to surgery 445 days. 45% of patients had an aggravation of the symptoms and they said this while filling the DASH questionnaire and VAS scale. Patients who underwent decompression and anterior transposition of the nerve consisted of 17 persons („transposition group”). Patients with in situ release were 23 („in situ group”). Patients with ultrasound signs of subluxation of the nerve had the same sign during the operation.

After in situ release, there was higher difference in cross-sectional area of the nerve than in cases with subcutaneous transposition after three months postoperatively. In the group of „in situ release” the mean cross-sectional area of the nerve was 16.1mm<sup>2</sup>, after 3 months post operation it was 10.9 mm<sup>2</sup>, and after six months it was 10.5 mm<sup>2</sup>. In the „transposition” group the mean cross-sectional area of the nerve was 15 mm<sup>2</sup>, after 3 months post operation it was 12 mm<sup>2</sup>, and after six months it was 10.9 mm<sup>2</sup>. Presence of

Table1. Shapiro-Wilk normality test for variables.

„transposition” group	DASH before op	SW-W = 0.8676	p = 0.0201
	DASH 3 months after	SW-W = 0.9385	p = 0.3011
	DASH 6 months after	SW-W = 0.9312	p = 0.2282
„in situ” group	DASH before op	SW-W = 0.896	p = 0.0209
	DASH 3 months after	SW-W = 0.5386	p = 0.00000
	DASH 6 months after	SW-W = 0.4858	p = 0.00000

neural branches and presence of perineurium were similar in both group. 27 patients had hourglass' sign before operation. After operations we noticed disappearance of this sign in 23 patients. There was significant improvement in DASH score 3 months postoperatively for both surgical methods (Tab. 2. and 3). The mean DASH score after in situ release was close

to 0 (Fig. 2). There was also significant improvement in VAS scale after six months post operations (Tab 4). Two patients six months after anterior transposition of the ulnar nerve complained of the pain while keeping the elbow in flexion position on the table. It was associated with a small amount of subcutaneous tissue.

Table 2. DASH score for „transposition” group. Comparison of variables with the use of nonparametric ANOVA.

Variable	Friedman ANOVA Chi <sup>2</sup> ANOVA (N = 17, df = 2) = 32.10909 p = 0.00000			
	Averagerank	Sum of ranks	Mean	Standard deviation
DASH before	3.000000	51.00000	69.11765	13.50871
DASH (3 months after)	1.617647	27.50000	22.41176	13.61781
DASH (6 months after)	1.382353	23.50000	20.20588	12.89266

Table 3. DASH score for „in situ” group. Comparison of variables with the use of nonparametric ANOVA.

Variable	Friedman ANOVA Chi <sup>2</sup> ANOVA (N = 23, df = 2) = 44.33333 p = 0.00000			
	Averagerank	Sum of ranks	Mean	Standard deviation
DASH (before)	3.000000	69.00000	63.65217	14.14731
DASH (3 months after)	1.565217	36.00000	3.74783	7.96600
DASH (6 months after)	1.434783	33.00000	1.90870	4.23834

Table 4. VAS score for both groups.

Variable	Wilcoxon matched-pairs signed-ranks test			
	N	T	Z	p
VAS & VAS (after 6 months) „transposition” group	17	0.00	3.621365	0.000293
VAS & VAS (after 6 months) „in situ” group	23	0.00	4.197264	0.000027

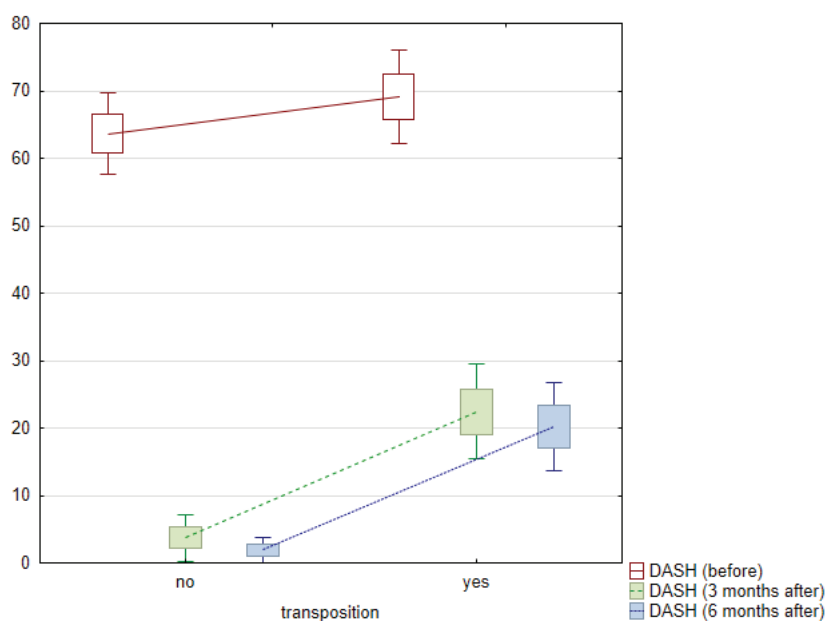


Fig. 2. Changes in DASH score in both groups.



## Discussion

The debate about optimal surgical technique for cubital tunnel syndrome is still opened. The current literature contains numerous studies comparing available methods. In our investigation we did not make comparison, but we took into consideration postoperative patients self-reporting instruments and sonographic outcomes.

The ultrasound examination is one of the diagnostic tool which we can use to diagnose cubital tunnel syndrome in patients with clinical symptoms. Ultrasound is easy to perform and has a short learning curve. In our study we use ultrasound examination not only in diagnosing but also as a control examination after surgery. (Figs. 3 and 4) It was not aggravating for the patients. Duetzmann et al. described their investigation in which they made ultrasound examination postoperatively in 48 patients who underwent surgical decompression of the ulnar nerve. In their study they found a slight reduction in the mean value of the cross-sectional area of the nerve. They draw a conclusion that ultrasound examination seems to be of limited in follow up after surgery [12]. In our investigation we saw higher reduction in cross-sectional area of the ulnar nerve postoperatively. We also saw disappearance of hourglass' sign. Our population was almost similar to Duetzmann et al. We think that further study should be made in this aspect.

To check patients' satisfaction we use DASH questionnaire, which contains 30 questions about patients' symptoms during some daily activities. We also used VAS scale about numbness and pain. In our study we found significant improvement in DASH and VAS scores. Similar conclusion was made by Zimmerman et al. and Ido et al. [13, 14]. Our investigation showed higher and faster improvement in cases of simple decompression.

In 2005 Nabhan et al. described a comparison of simple decompression to subcutaneous anterior transposition of the ulnar nerve for cubital tunnel syndrome. In their study, they paid attention to sensory deficits, ulnar intrinsic motor power, pain (using VAS) and nerve conduction velocity before surgery, 3 and 9 months postoperatively. They examined 66 patients (32 with in situ release, 34 with anterior transposition) and they found no difference between these two operations, but they suggest simple decompression as a less extensive procedure [2]. They did not use patient-reported outcomes. Our study found that recovery after in situ release has rapid early improvement in patients self-reporting outcome metrics. We did not find slower recovery in older patients. Maybe its because first follow up was after 3 months. Similar trend of patients' recovery after simple decompression were described by Giladi et al. In their investigation they conclude that recovery after in situ release of the ulnar nerve at the elbow occurs in the first 6 weeks postoperatively and reach a plateau at 3 months [15]. In this study they did not describe timing of recovery after anterior subcutaneous transposition.

Saint-Cyr et al. (2013) presented their study in which they compared four surgical techniques: simple decompression, endoscopic decompression, anterior subcutaneous transposition and anterior submuscular transposition. They concluded that every technique are good to treat cubital tunnel syndrome and the selection of the technique should depend on surgeons' experience [3].

In 2014 Chen et al. made a meta-analysis about the comparison of these two surgical methods. They drew a conclusion that both in situ release and anterior subcutaneous transposition have similar clinical outcomes but simple decompression should be preferred owing to lower incidence of complications" [8].

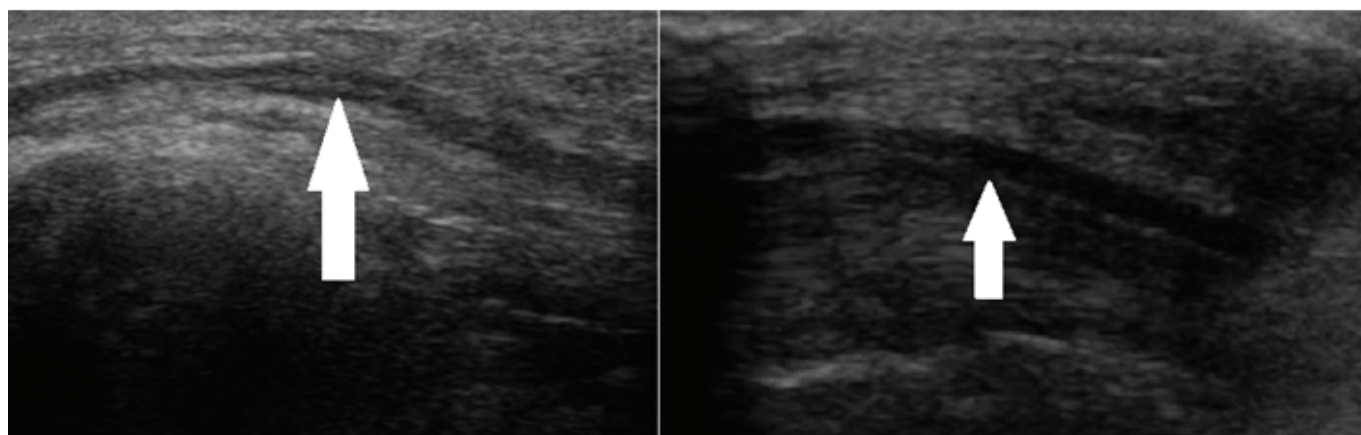


Fig. 3. The longitudinal views of the ulnar nerve at the elbow before (left figure) and after (right figure) operation. The ulnar nerve is marked with a white arrow.

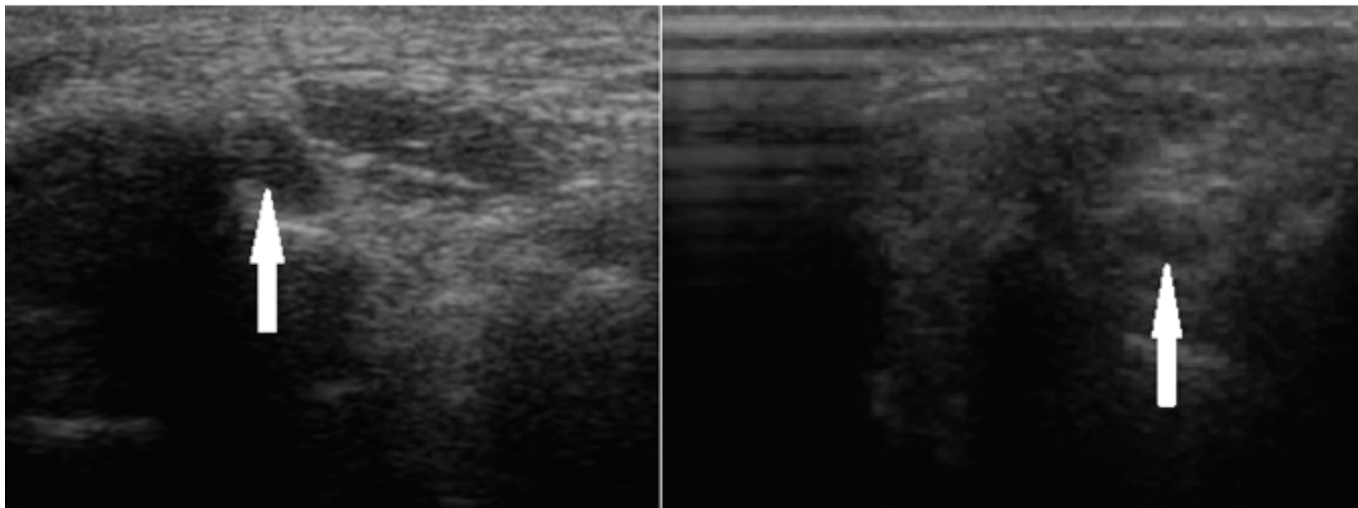


Fig. 4. The transverse views of the ulnar nerve at the elbow before (left figure) and after (right figure) operation. The ulnar nerve is marked with a white arrow.

## Conclusion

According to our results we suggest that both methods are good enough to treat the cubital tunnel syndrome. Simple decompression damages nerve blood supply to a lesser extent in the opposite to anterior transposition because anterior transposition requires decompression of the nerve for a distance of up to more less 10cm. During in situ release we also leave the nerve in its normal anatomical position without interfering with the surrounding soft tissues.

Our results indicate that patients' postoperative satisfaction measured with patients self-reporting instruments is higher after simple decompression, but both methods help to relief symptoms. Ultrasound examination showed faster recovery of the nerve after in situ release. Maybe it is because of less interfering in the tissues.

### Abbreviations

DASH – The Disabilities of the Arm, Shoulder and Hand Score

VAS – The Visual Analogue Scale

## References

- Mitchell J, Dunn JC, Kusnezov N, Bader J, Ipsen DF, Forthman Ch, Dykstra A: The effects of operative technique on ulnar nerve strain following surgery for cubital tunnel syndrome. *Hand*. 2015, 10: 707-11.
- Nabhan A, Ahlhelm F, Kelm J, Reith W, Schwerdtfeger K, Studel WI: Simple decompression or subcutaneous anterior transposition of the ulnar nerve for cubital tunnel syndrome. *J Hand Surg*. 2005, 30B: 521-24.
- Saint-Cyr M, Lakhiani Ch, Tsai TM: Surgical management of cubital tunnel syndrome: a comparative analysis of outcome using four different techniques. *Eur J Plast Surg*. 2013, 36: 693-700.
- Dellon AL: Review of treatment results for ulnar nerve entrapment at the elbow. *J Hand Surg AM*. 1989, 14: 688-700.
- Kutley M, Olak A, Şimşek H, Öztürk E, Güney M, Topuz K et al.: Use of ultrasonography in ulnar nerve entrapment surgery – a prospective study. *Neurosurg Rev*. 2009; 32: 225-232.
- Okamoto M, Abe M, Shirai H, Ueda N. Morphology and dynamics of the ulnar nerve in the cubital tunnel. Observation by ultrasonography. *J Hand Surg Eur*. 2000;25: 85-9.
- Bartels RH: History of the surgical treatment of ulnar nerve compression at the elbow. *Neurosurgery*. 2001, 49: 391-99.
- Chen HW, Ou S, Liu GD, Fei J, Zhao GS, Wu LJ, Pan J: Clinical efficacy of simple decompression versus anterior transposition of the ulnar nerve for the treatment of cubital tunnel syndrome: A meta-analysis. *Clin Neurol Neurosurg*. 2014, 126: 150-55.
- Cirpar M, Turker M, Ozuak CS. Distal medial epicondylectomy. A modification of partial medial epicondylectomy for cubital tunnel syndrome: preliminary results. *Arch Orthop Trauma Surg*. 2012, 132: 1569-75.
- Damert HG, Altmann S, Infanger M, Kraus A. Operative Decisions for Endoscopic Treatment of Cubital Tunnel Syndrome. *Orthopedics*. 2013, 36: 354-59.
- Chang KV, Wu WT, Han DS, Zhang L: Ulnar Nerve Cross-Sectional Area for the Diagnosis of Cubital Tunnel Syndrome: A Meta-Analysis of Ultrasonographic Measurements. *Arch Phys Med Rehabil*. 2017, S0003-9993: 31071-7.
- Duetzmann S, Krishnan KG, Staub F, Kang JS, Seifert V, Marquardt G: Cross-sectional area of the ulnar nerve after decompression at the cubital tunnel. *J Hand Surg Eur*. 2016; 41:838-42.
- Zimmerman N, Kaye M, Wilgis EF, Zimmerman R, Dubin N: Are standardized patient self-reporting instruments applicable to the evaluation of the ulnar neuropathy at the elbow? *J Shoulder Elbow Surg*. 2009; 18: 463-468.
- Ido Y, Uchiyama S, Nakamura K, Itsubo T, Hayashi M, Hata Y et al.: Postoperative improvement in DASH score, clinical findings, and nerve conduction velocity in patients with cubital tunnel syndrome. *Sci Rep*. 2016; 6:1-8.
- Giladi A, Gaston G, Haase S, Hammert W, Lawton J, Merrell G et al.: Trend of recovery after simple decompression for treatment of ulnar neuropathy at the elbow. *Plast Reconstr Surg*. 2013; 131: 563e-573e.